



PATIENT

Buddy Watts

SPECIES

Canine

BREED

Havanese

SEX

MN

AGE

13 years

WEIGHT

29 #

INTERPRETED BY

Remo Lobetti, BVSc,
MMedVet (Med),
PhD, Dipl. ECVIM

**IMAGING
PERFORMED BY**

Lara Wiseman, DVM

HOSPITAL NAME

Village Royale Animal
Clinic

REFERRING VET

INVOICE

302712

DATE

1/28/22

PRESENTING CLINICAL SIGNS

History: Renoliths.

Physical Examination: N/A.

Urinalysis: N/A.

CBC: Mild anemia.

Serum Biochemistry: Elevated liver enzyme activity, azotemia, hyperphosphatemia. Normal ACTH stimulation test.

Radiographic Findings: N/A.

ULTRASONOGRAPHIC EXAMINATION OF THE ABDOMEN

Urinary System

Full urinary bladder with a normal appearance and thickness of the wall. Small amount of hyperechogenic floating sediment and focal urolith (0.8 cm).

Normal trigone area, proximal urethra (0.33 cm), and iliac blood vessels.

Normal iliac lymph nodes. Ureters not visualized.

Normal renal size (left 5 cm, right 5.2 cm) with increased echogenic appearance, loss of cortico-medullary differentiation, irregular capsule, pyelectasia (left 0.26 cm, right 0.46 cm), and bilateral cortical cysts.

Reproductive System

Small hypoechogenic prostate (0.9 cm).

Adrenal Glands

Left – normal shape, echogenic appearance, size (0.39 cm), and position.

Irregular right adrenal mass (1.6 x 2.7 cm) with a mottled echogenic appearance. Hyperechogenic appearance of the surrounding mesentery.

Spleen

Normal size and echogenic appearance. Smooth homogenous parenchyma, smooth curvilinear capsule, and normal vasculature. No evidence of inflammatory, neoplastic, infarction, or infiltrative changes noted. Incidental myelolipomas.

Liver

Enlarged with rounded edges, diffuse mottled and nodular echogenic appearance, and loss of portal markings. No masses evident. Full gall bladder containing normal anechoic bile. Normal thickness and appearance of the gall bladder wall. Normal bile duct (0.25 cm).



PATIENT

Buddy Watts

SPECIES

Canine

BREED

Havanese

SEX

MN

AGE

13 years

WEIGHT

29 #

INTERPRETED BY

Remo Lobetti, BVSc,
MMedVet (Med),
PhD, Dipl. ECVIM

IMAGING PERFORMED BY

Lara Wiseman, DVM

HOSPITAL NAME

Village Royale Animal
Clinic

REFERRING VET

INVOICE

302712

DATE

1/28/22

Gastrointestinal

Normal appearance of the gastro-esophageal junction, stomach, duodenum, small intestine, ileo-cecal junction, and colon with no loss of layering, normal wall thickness (stomach 0.53 cm, duodenum 0.45 cm, jejunum 0.36 cm, colon 0.23 cm) and peristalsis, and no distension of the lumen.

Pancreas

Normal size (1.3 cm) and echogenic appearance. Regular capsule. Normal echogenic appearance of the mesentery and fat surrounding the pancreas.

Free Abdomen

No mesenteric lymphadenomegaly.
No ascites.

ULTRASONOGRAPHIC FINDINGS

Primary findings:

- Renal disease.
- Nodular hepatopathy.
- Right adrenal mass.
- Uroliths.

Secondary findings:

- None.

INTERPRETATION OF THE FINDINGS & FURTHER RECOMMENDATIONS

The appearance of the kidneys is consistent with chronic kidney disease with pyelonephritis and bacterial nephritis, differential diagnoses.

Etiologies for the nodular hepatopathy would be reactive, hyperplasia, nodular regeneration, chronic hepatitis, early cirrhosis, granulomatous disease, and infiltrative neoplasia.

The appearance of the right adrenal gland is typical for neoplasia, which is either a pheochromocytoma or non-functional.

Further assessment would be urinalysis, urine culture, blood pressure, 3-view thoracic radiographs, and FNA cytology of the liver and adrenal mass.

Specific therapy would be dependent on an etiological diagnosis.



PATIENT

Buddy Watts

SPECIES

Canine

BREED

Havanese

SEX

MN

AGE

13 years

WEIGHT

29 #

INTERPRETED BY

Remo Lobetti, BVSc,
 MMedVet (Med),
 PhD, Dipl. ECVIM

IMAGING PERFORMED BY

Lara Wiseman, DVM

HOSPITAL NAME

Village Royale Animal
 Clinic

REFERRING VET

INVOICE

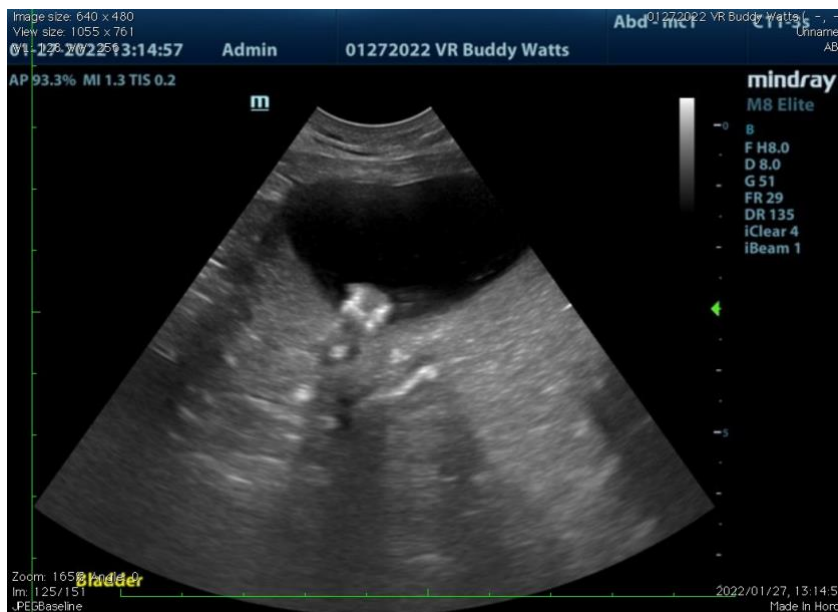302712

DATE

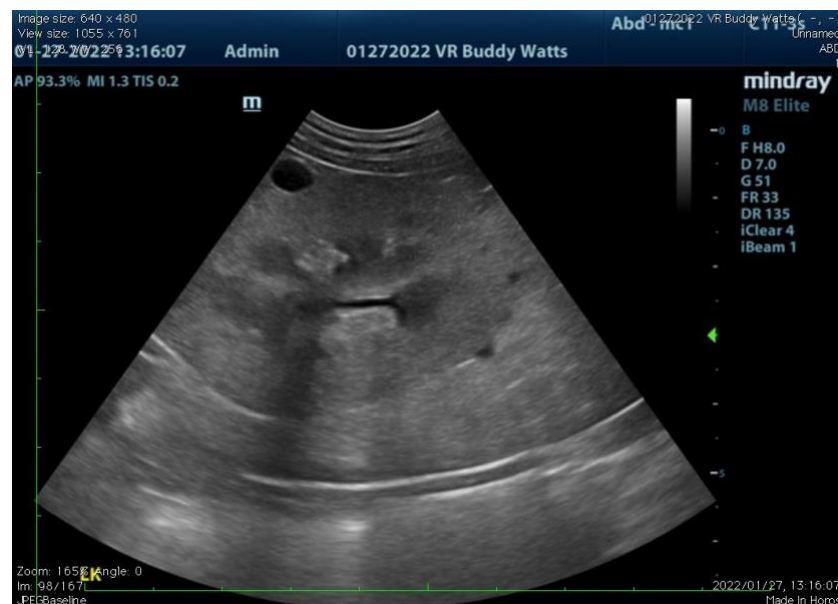1/28/22

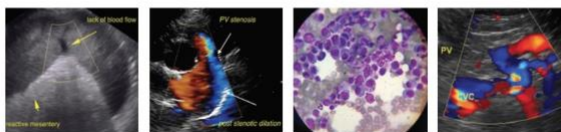
IMAGES

Urinary bladder



Kidney





PATIENT

Buddy Watts

SPECIES

Canine

BREED

Havanese

SEX

MN

AGE

13 years

WEIGHT

29 #

Liver

INTERPRETED BY

Remo Lobetti, BVSc,
 MMedVet (Med),
 PhD, Dipl. ECVIM

IMAGING PERFORMED BY

Lara Wiseman, DVM

HOSPITAL NAME

Village Royale Animal
 Clinic

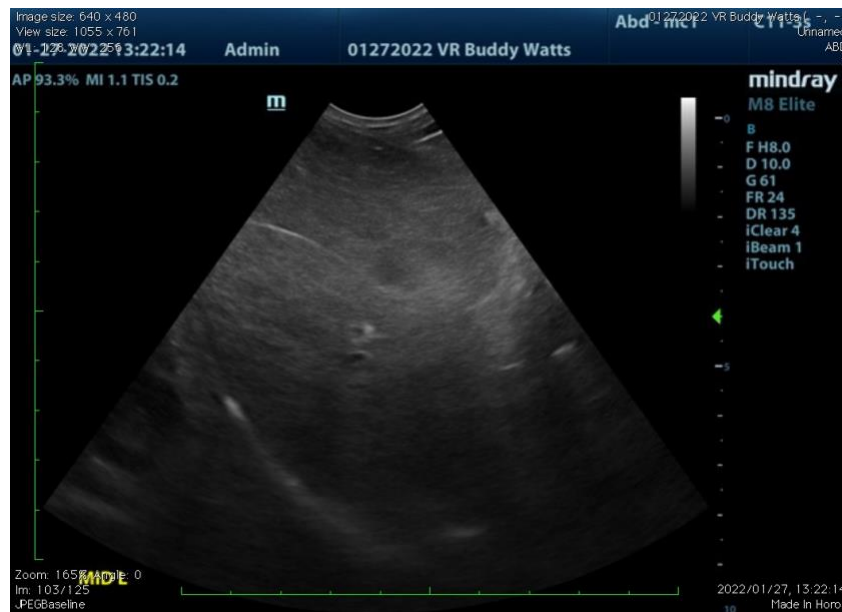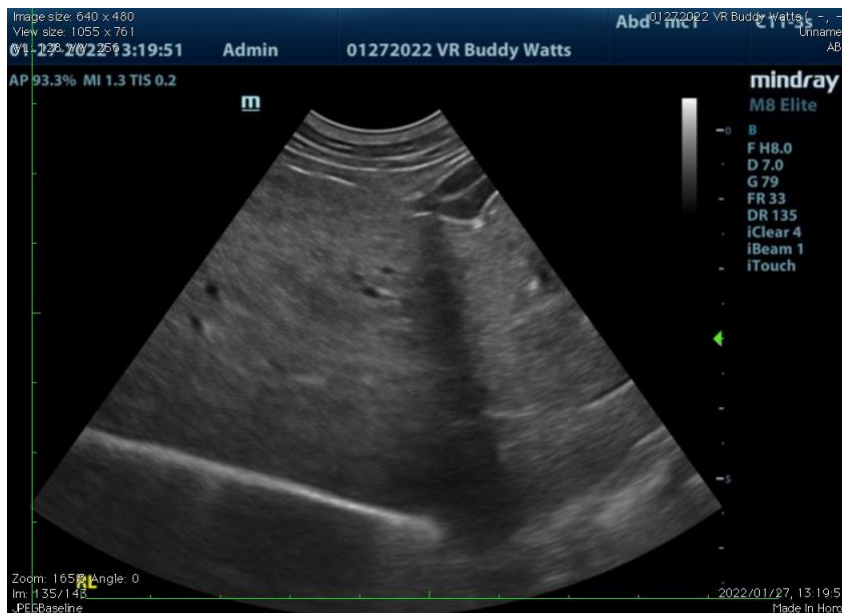REFERRING VET

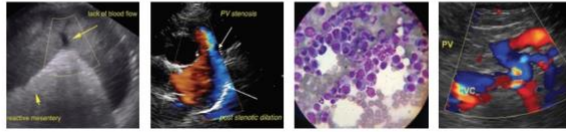
INVOICE

302712

DATE

1/28/22





PATIENT

Buddy Watts

SPECIES

Canine

BREED

Havanese

SEX

MN

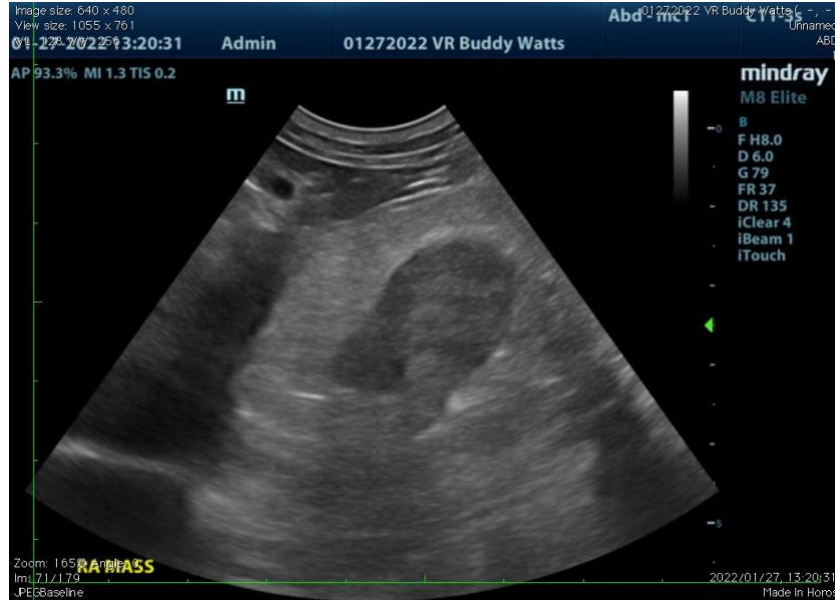AGE

13 years

WEIGHT

29 #

Right adrenal



INTERPRETED BY

Remo Lobetti, BVSc,
MMedVet (Med),
PhD, Dipl. ECVIM

IMAGING PERFORMED BY

Lara Wiseman, DVM

HOSPITAL NAME

Village Royale Animal
Clinic

REFERRING VET

INVOICE

302712

DATE

1/28/22

The information and recommendations provided are based on the images presented by the referring veterinarian. No evaluation can be communicated regarding pathology that was not visible in the image/video clips provided.

Thank you for this referral. If the clinical or image interpretation does not parallel your findings or if I can be of any further assistance please contact me.

Remo Lobetti, BVSc, MMedVet (Med), PhD, Dipl. ECVIM (Internal Medicine)
rlobetti@mweb.co.za